



Original Article:

Morphological Analysis of the Human Internal Iliac Artery in South Indian Population

Naveen NS, Assistant Professor, Department of Anatomy, KMCT Medical College, Calicut University, Calicut, India,
Murlimanju BV, Assistant Professor, Department of Anatomy, Kasturba Medical College, Manipal University, Mangalore, India,
Vishal Kumar, Assistant Professor, Department of Anatomy, KS Hegde Medical Academy, Nitte University, Mangalore, India,
Jayanthi KS, Professor, Department of Anatomy, Kempegowda Institute of Medical Sciences, Bangalore,
Krishna Rao, Professor, Department of Anatomy, Kempegowda Institute of Medical Sciences, Bangalore,
Thejodhar Pulakunta, Assistant Professor, Department of Anatomical Sciences, St. Matthew's University School of Medicine, Grand Cayman Islands, BWI.

Address For Correspondence:

Dr. B.V. Murlimanju,

Assistant Professor,

Department of Anatomy,

Kasturba Medical College,

Manipal University,

Mangalore - 575004, India.

E-mail: flutesnowmm@gmail.com

Citation: Naveen NS, Murlimanju BV, Kumar V, Jayanthi KS, Rao K, Pulakunta T. Morphological Analysis of the Human Internal Iliac Artery in South Indian Population. *Online J Health Allied Scs.* 2011;10(1):11

URL: <http://www.ojhas.org/issue37/2011-1-11.htm>

Open Access Archives: <http://cogprints.org/view/subjects/OJHAS.html> and <http://openmed.nic.in/view/subjects/ojhas.html>

Submitted: Feb 11, 2011 Accepted: Mar 31, 2011; Published: April 15, 2011

Abstract:

Objectives: The accidental hemorrhage is common due to erroneous interpretation of the variant arteries during surgical procedures, hence the present study has been undertaken with reference to its morphological significance. The objectives were to examine the level of origin, length and the branching pattern of the human internal iliac artery in South Indian population.

Methods: The study included 60 human bisected pelvises irrespective of their side and sex. The specimens were collected from the anatomy laboratory and were fixed with the formalin. The branching patterns were studied and demonstrated as per the guidelines of Adachi. **Results:** The origin of internal iliac artery was at the level of S1 vertebra in majority (58.3%) of the cases. The average length of internal iliac artery was 37 ± 4.62 mm (range, 13-54 mm). The type I pattern of the internal iliac artery was most common (83.5%) followed by types III and II. The type IV and V pattern of adachi were not observed. **Conclusions:** The results of this study were different from those reported by others and may be because of racial and geographical variations. Prior knowledge of the anatomical variations is beneficial for the vascular surgeons ligating the internal iliac artery or its branches and the radiologists interpreting angiograms of the pelvic region.

Key Words: Anatomy; Branches; Classification; Internal iliac artery; Ligation; Variations

Introduction:

The internal iliac artery (IIA) originates from the common iliac artery at the level of sacroiliac joint,(1,2) descends posterior to the greater sciatic foramen and divides into anterior and posterior divisions.(1,2) The branches of the anterior division include superior vesical artery, inferior vesical artery, middle rectal artery, vaginal artery, obturator artery, internal pudendal artery and the inferior gluteal artery.(1,2) The posterior division gives three branches i.e. iliolumbar artery, lateral sacral artery and the superior gluteal artery.(1,2) As per the previous observations,

during the development, the most appropriate channels enlarge and the others get retracted or disappear, which will result in the final arterial pattern.(3) During development, the IIA derives from the umbilical artery which persists in its proximal part and the distal part gets obliterated postnatally.(4)

The proper knowledge and its branching pattern of the IIA will provide the surgeon proper guidelines in ligating the artery and its branches during various surgical procedures of the pelvic viscera. There are only a few studies available in the literature regarding the morphology of the IIA and from india are not reported. Hence the present study has been undertaken with reference to its morphological significance. The objectives were to note the level of origin of the IIA and to measure the length of its trunk, to note the level of its division and its branching pattern.

Methods:

The study included 60 human cadaveric bisected pelvises which were available in the department of anatomy and were preserved in 10% formaldehyde solution. The study was performed as per the guidelines of the institutional ethical committee. No particular emphasis was given to the side, gender and age of the pelvises. No particular method was employed for the dissection but care was taken to expose the branches of the IIA. The IIA along with its anterior and posterior divisions and its further subdivisions, were carefully delineated by separating it from the surrounding structures. Morphometric measurements were taken using a vernier caliper of 2mm accuracy with the pelvis in supine position and the specimens were photographed. The measurements were taken from the point of bifurcation of the common iliac artery to its point of division. To avoid bias, the measurements were taken by two different authors. The level of origin of IIA from the common iliac artery was also noted. The branching patterns of IIA were studied and demonstrated as per the guidelines of Adachi.(5) The Adachi's pattern used in the present study, distinguishes the IIA into five different types as follows (Fig. 1):

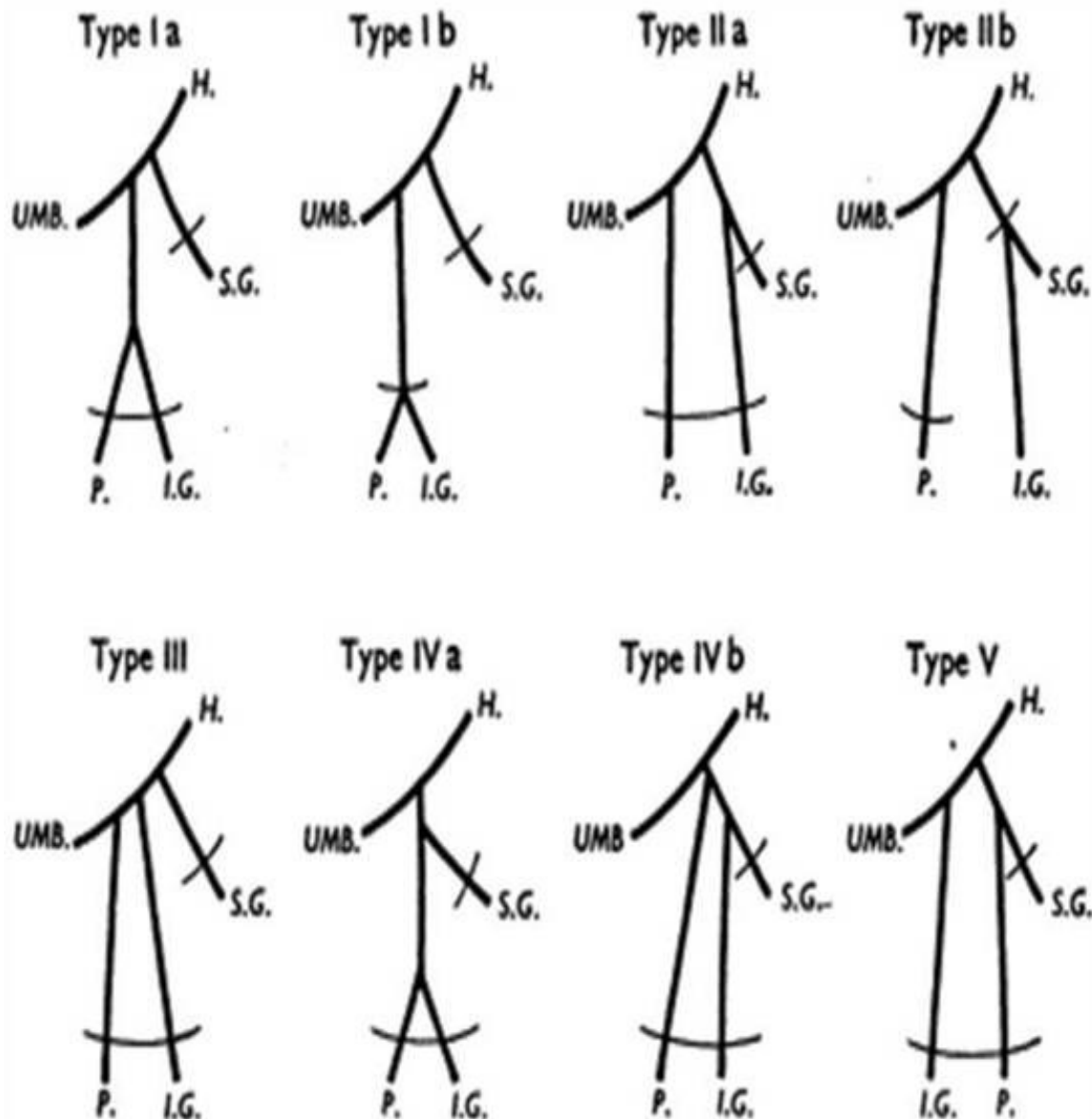


Fig. 1: Schematic Representation of Adachi's types. H. internal iliac artery; I.G. inferior gluteal artery; P. internal pudendal artery; S.G. superior gluteal artery; UMB. Umbilical artery. (Braithwaite J.L., 1952)

Type I - The superior gluteal artery arises separately from the IIA, the inferior gluteal and internal pudendal vessels are given off by a common trunk. If the latter divides within the pelvis it is considered to be Type Ia, whereas if the bifurcation occurs below the pelvic floor it is classified as Type Ib. Type II - The superior and inferior gluteal arteries arise by a common trunk and the internal pudendal vessel separately. In this category, as in the previous one, two subtypes are described. Type IIa includes those specimens in which the trunk common to the two gluteal arteries divides within the pelvis and Type IIb those in which the division occurs outside the pelvis. Type III - The three branches arise separately from the internal iliac artery. Type IV - The three arteries arise by a common trunk. The subtyping in this group is based on the sites of origin of the superior gluteal and the internal pudendal arteries from the parent stem. In Type IVa the trunk first gives rise to the superior gluteal artery before bifurcating into the other two branches; in Type IVb the internal pudendal is the first vessel to spring from the common trunk, which then divides into superior and inferior gluteal arteries. Type V - The internal pudendal and the superior gluteal arteries arise from a common trunk and the inferior gluteal has a separate origin.

Results:

The origin of IIA was at the level of S1 vertebra in 35 cases (58.3%), at the level of L5-S1 in 24 cases (40%) and in 1 case (1.7%), it was at the level of L5 (Fig. 2A). From the morphometrical analysis, values ranged between 13 and 54 mms and the average length being 37 ± 4.62 mms. The Adachi's (5) guideline was followed, where the IIA ends at the emergence of the gluteal artery. It has been observed that the IIA divided proximal to the upper edge of greater sciatic notch in all the 60 specimens. The distance from the greater sciatic notch is 3 cms above in 18 cases (30.7%), 2 cms above in 14 (23.1%) cases, 2.5 cms above in 12 specimens (19.8%), 4 cms above in 8 cases (13.2%), 3.5 cms above 4 cases (6.6%) and 5.5 cms above the greater sciatic notch in 4 cases (6.6%). Fig. 2B shows the incidence of the branching pattern of IIA, as per Adachi's guidelines. The branching pattern of IIA was Type Ia (Fig. 3A) in 46 (76.9%) of the cases, Type Ib (Fig. 3B) in 4 (6.6%), Type IIa (Fig. 4A) in 4 (6.6%) of cases and Type III (Fig. 4B) in 6 (9.9%) cases. The type IV and V pattern of adachi (5) were not observed in the present study.

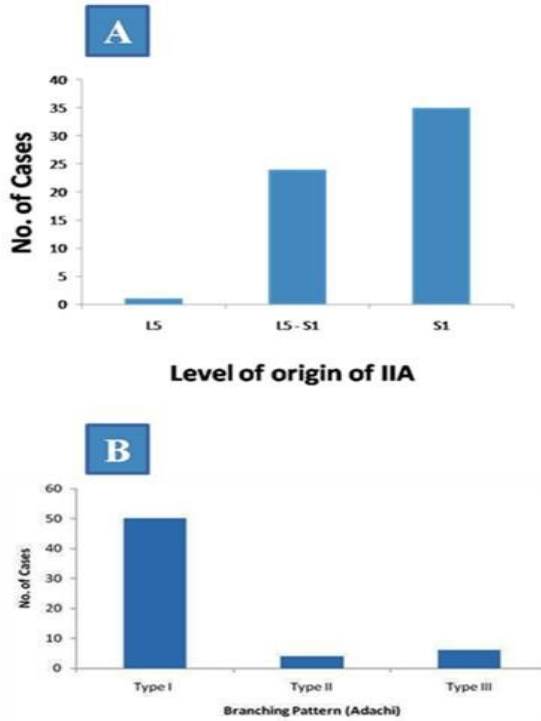


Fig 2A. Histogram showing the incidence of the origin of IIA at different levels (n = 60) 2B. Histogram showing the incidence of the branching pattern of IIA (as per Adachi) (n = 60)

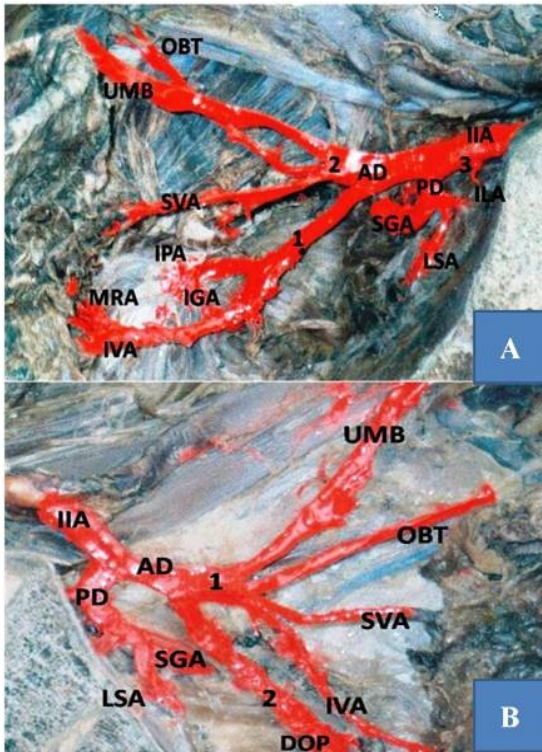


Fig 3A: Internal Iliac Artery Type Ia (1 - a common trunk from AD giving IPA, IGA & IVA; 2 - a common trunk from AD giving UMB & SVA; 3 - IIA arising from the trunk of IIA)

3B: Internal Iliac Artery Type Ib (1 - a common trunk from AD giving UMB, SVA, IVA & OBT; 2 - a common trunk from AD giving IGA & IPA outside (DOP) the pelvis)

(IIA - internal iliac artery, UMB - umbilical artery, OBT - obturator artery, SVA - superior vesical artery, IVA - inferior vesical artery, SGA - superior gluteal artery, IGA - inferior gluteal artery, IPA - internal pudendal artery, MRA - middle rectal artery, LSA - lateral sacral artery, ILA - iliolumbar artery, AD - anterior division, PD - posterior division)

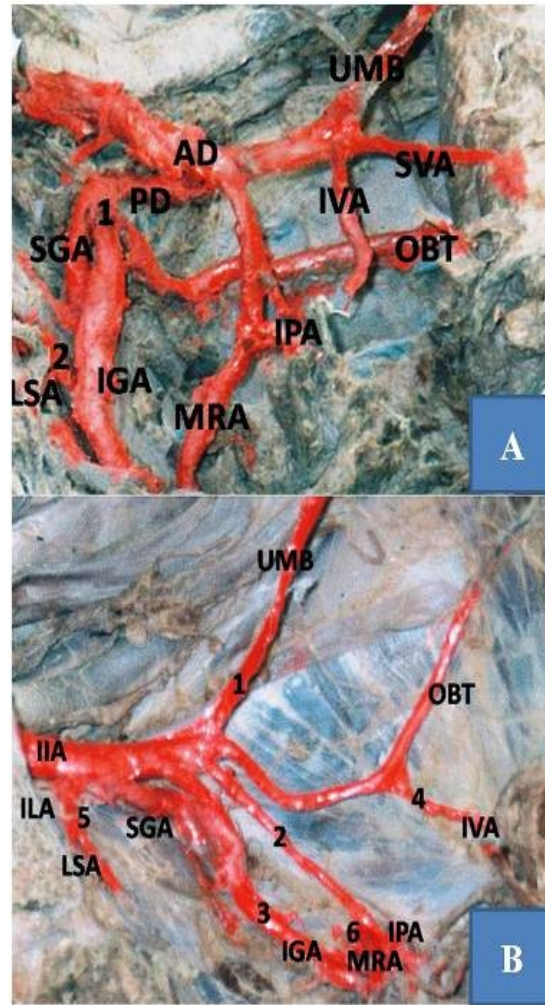


Fig 4A: Internal Iliac Artery Type IIa (1 - a common trunk from PD giving SGA, IGA & OBT; 2 - LSA arising from IGA)

4B: Internal Iliac Artery Type III (1 - UMB arising separately from AD; 2 - IPA arising separately from AD; 3 - IGA arising separately from AD; 4 - IVA arising from OBT; 5 - LSA arising from trunk of IIA; 6 - MRA arising from IPA)

(IIA - internal iliac artery, UMB - umbilical artery, OBT - obturator artery, SVA - superior vesical artery, IVA - inferior vesical artery, SGA - superior gluteal artery, IGA - inferior gluteal artery, MRA - middle rectal artery, IPA - internal pudendal artery, LSA - lateral sacral artery, ILA - iliolumbar artery, AD - anterior division, PD - posterior division)

Discussion:

The accidental hemorrhage is common due to erroneous interpretation of the variant arteries by the surgeons and a thorough knowledge of the anatomy of the branches of the IIA is essential. Hemorrhage has been considered as the leading cause of maternal deaths in the developing countries. (6) The ligation of the IIA to control hemorrhage during pelvic surgeries has been described by Kelly HA (7) as early as in 1894. Recent reports opine that the efficacy of the IIA ligation during any obstetrics and gynecology surgery varies between 42-75%. (8,9) So it is obvious that, for the successful ligation of IIA the surgeon should have a sound knowledge of the anatomy of its anterior and the posterior divisions.

The visceral branches of IIA supply the urinary bladder, rectum, prostate, seminal vesicles, ejaculatory ducts in males and the gonads, uterus, vagina, urinary bladder, urethra in females. The gluteal region, posterior and antero-medial regions of the thigh and the hip joint are supplied by the extra pelvic branches of the IIA. It was reported that the examination of IIA is very useful clinically because of its large territory of distribution, its role in the embryo-fetal circulation and the possibility of its atrophic ligature in non-surgical malignancies.(10,11) The first attempt to group the variations of the parietal branches of the IIA was undertaken by Jastschinski.(12) In an extensive study of the polish subjects, he classified the vessels into those of large caliber, those of medium caliber and those of small caliber. He found that only the first category showed sufficient regularity in origin to enable them to be grouped into definite types, of which he described four. Adachi (5) modified the Jastschinski's (12) method slightly, adding a fifth type of variation and subtypes, in a study from Japanese subjects. Now there are a few reports available (5,12-14) on the morphology of IIA and the authors of those reports classified the IIA based on the variations in the origin of parietal branches. Jastschinski (12) and Adachi (5) noted four main parietal branches of IIA namely umbilical, superior gluteal, inferior gluteal and internal pudendal artery. Ashley and Anson (14) in their study from 130 specimens observed the inferior and superior gluteal artery arising from one common stem in 58% of the cases, the internal pudendal and umbilical arteries arising from other common stem in 17%, the inferior and superior gluteal arteries from one common stem, the internal pudendal and umbilical from other common stem in 8% of the cases, the umbilical and internal pudendal arteries arose separately above the common stem for gluteal artery. Yamaki et al. (15) from their study based on the dissection of 645 pelvic halves of Japanese cadavers, the branching of IIA was classified into 4 groups. Almost 80% of the specimens were included in group A, i.e. the IIA dividing into two major branches, the superior gluteal artery and the common trunk for the inferior gluteal and internal pudendal arteries. According to Adachi (5) (Fig. 1), the type I pattern was found in 51.2% of the cases, type II in 23%, type III in 18% and type IV in 4.1% of the cases. In contrast, Fatu et al. (16) found type I pattern in 60 out of 100 cases, type II in 20 cases, type III in 10 cases, type IV in one case and type V was found in 18 cases. From a study conducted by Braithwaite,(17) type I arrangement was seen in 58.5 % of cases, type III in 22.5 % and type II in 15.3 %. The type IV was less frequent and occurred in 3.86 % of specimens. According to a study by Inomata et al.(18) from 78 cadavers, the type I pattern of Adachi was observed in 56.1% of the cases followed by types III, II, IV and V.

In the present study from guidelines of Adachi,(5) the branching pattern of IIA was type I (a) in majority of the specimens. The type I ending was seen in 83.5% of the cases which includes type I (a) and type I (b). This finding is similar to other reports,(12,13) in which the common branching pattern was type I. In the present study, the types IV and V were not observed and there were a few different observations made, from the other studies. This may be because the racial and geographical variations seemed to exist.

According to Williams et al.(1) the IIA arises at the level of the L5-S1 intervertebral disc and anterior to sacroiliac joint. However, in the present study, the origin of IIA was at the level of S1 in majority of the specimens. It was reported that the length of IIA is variable, depends on the length of the common iliac artery and the level of division of the IIA.(19) It was also reported(19) that the length of the IIA may be as short as 1.2 cms or as long as 7.5 cms and it is seldom less than 2.5 cms in length. The same authors reported that, in some cases the branches arise without the artery dividing into anterior and posterior divisions and one or more branches arise above the division. According to Fatu et al,(16) the length of the IIA ranged between 20 and 90 mm, mean value being 49 mm. The average length of IIA was 27.0 (range, 0-52) mm, according to Bleich et al.(20) In the present study, the average length of IIA was 37 ± 4.62 (range, 13-54) mms. This is slightly lesser compared to Fatu et al.(16) finding and may be because of racial variations. The gracile Indian subjects may have shorter arteries than more robustly built subjects from other ethnic groups. According to Williams et al, (1) the IIA divides at the level of superior edge of greater sciatic notch. In the present study it has been observed that the IIA divided proximal to the upper edge of greater sciatic notch in all the 60

specimens and the distance from the greater sciatic notch is 3 cms in majority of the specimens.

Conclusion:

This study highlights the variations seen in origin, length, division and branching pattern of IIA in the South Indian population. Understanding the approximate location, orientation and anatomic relationships of the IIA should aid in preventing the blood loss and other potentially severe complications such as ureteral injury, vein laceration and ligation of the external iliac artery. In the event of acute hemorrhage, a detailed dissection of the IIA is not always feasible, if the surgeon has the detailed knowledge about the morphology of IIA, many such complications can be avoided. The other implications of this knowledge are to guide the interventional radiologists in intraarterial procedures during arterial embolization for hemorrhage control of pelvic fractures, during selective catheterization for intraarterial chemotherapy and embolizations for pelvic tumors. We believe that this study aims to explain the important aspects of the vascular anatomy of the IIA, not only for anatomists and morphologists, also for the radiologists, general and vascular surgeons.

References:

1. Williams PL, Bannister LH, Berry MM, Collins P, Dyson M, Dussek JE, Ferguson MWJ. Gray's Anatomy. The anatomical basis of medicine and surgery, 38th ed. Edinburgh; Churchill Livingstone; 1995. p. 1560.
2. Snell RS. Clinical anatomy for students, 6th ed. Philadelphia; Lippincott, Williams & Wilkins; 2000. p. 292-93.
3. Fitzgerald MJT. Human Embryology, New York; Harper International; 1978. p. 38-56.
4. Sadler TW. Langman's Medical Embryology, 6th ed. London; Williams & Wilkins Co: 1990.
5. Adachi B. Das Arteriensystem der Japaner, Bd. II. Kyoto. Supp. to Acta Scholae Medicinalis Universitatis Imperialis in Kioto 1928;9:1926-1927.
6. Cunningham FG, Leveno KJ, Bloom SL, Hauth JC, Gilstrap LC 3rd, Wenstrom KD (eds). Williams Obstetrics, 22nd ed. New York; McGraw-Hill Professional; 2005. p. 7-8.
7. Kelly HA. Ligation of both internal iliac arteries for haemorrhage in hysterectomy for carcinoma uteri. *Bull Johns Hopkins Hosp.* 1894;5:53-54.
8. Das BN, Biswas AK. Ligation of internal iliac arteries in pelvic haemorrhage. *J Obstet Gynaecol Res.* 1998; 24: 251-4.
9. Papp Z, Toth-Pal E, Papp C, et al. Hypogastric artery ligation for intractable pelvic hemorrhage. *Int J Gynaecol Obstet.* 2006;92:27-31.
10. Iliopoulos JI, Hermreck AS, Thomas AS, Pierce GE. Hemodynamics of the internal iliac arterial circulation. *J Vasc Surg.* 1989;9:637-641.
11. Gotta F, Kassaniou S, Gnagne Y, Gnanazan G. Internal iliac artery: functional anastomosis value and pelvic surgery application. *Morphologie.* 2003;87:39-45.
12. Jastschinski S. Die Tyischen Verzweigsform der Arteria Hypogastrica. *Int Mschr Anat Physiol.* 1891a;8:111-127.
13. Lipshutz B. A composite study of the hypogastric artery and its branches. *Ann Surg.* 1918;67:584-608.
14. Ashley FL and Anson BJ. Hypogastric artery in American Whites and Negroes. *Am J Phys Anthropol.* 1941;28:381-395.
15. Yamaki K, Saga T, Doi Y, Aida K, Yoshizuka M. A statistical study of the branching of the human internal iliac artery. *Kurume Med J.* 1998;45:333-340.
16. Fatu C, Puisoru M and Fatu IC. Morphometry of the internal iliac artery in different ethnic groups. *Ann Anat.* 2006;188:541-546.
17. Braithwaite JL. Variations in origin of the parietal branches of the internal iliac artery. *J Anat.* 1952;86:423-430.
18. Inomata Y, Sakuyama T, Watanabe K. Analysis of the Branching Pattern of the Human Internal Iliac Artery. *Jikeikai Med J.* 2000;47:75-92.
19. Bergman RA et al. Origin of the variable branches of Internal Iliac Artery, Virtual hospital illustrated encyclopedia of human anatomic variation opus II cardiovascular; 2002.
20. Bleich AT, Rahn DD, Wieslander CK et al. Posterior division of the internal iliac artery: Anatomic variations and clinical applications. *Am J Obstet Gynecol.* 2007;197:658.e1-e5.